

My procedure of PCL and PLC reconstruction

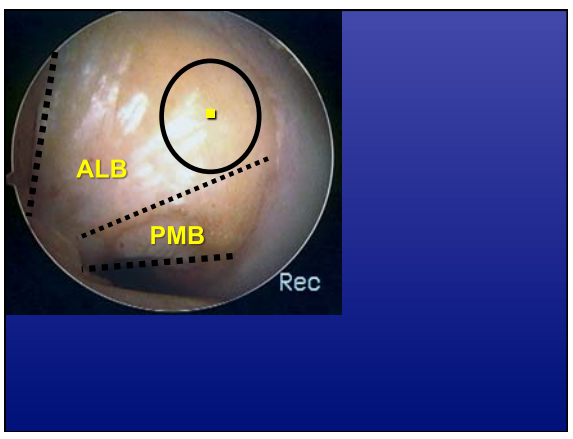
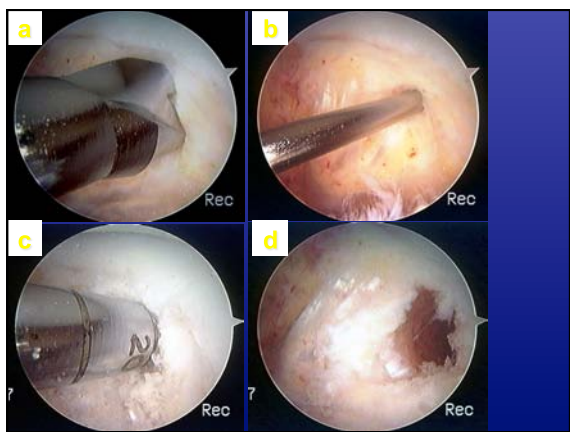
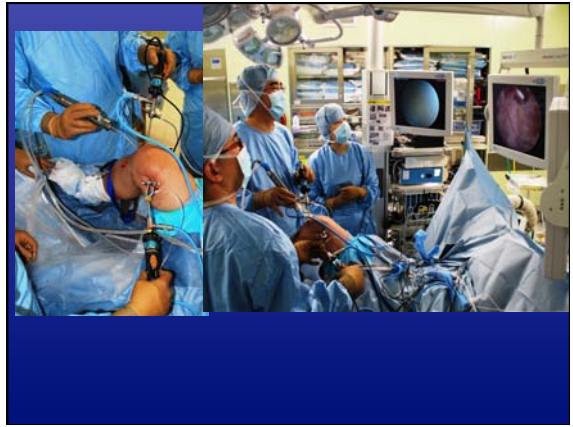
Mitsuo Ochi, MD  
Professor and chair  
Department of Orthopaedic Surgery  
Hiroshima university, Japan

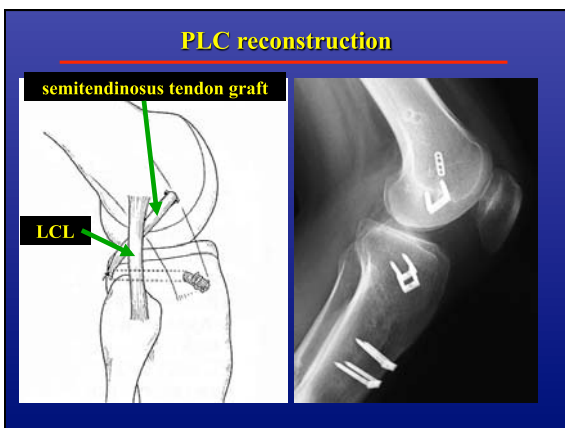
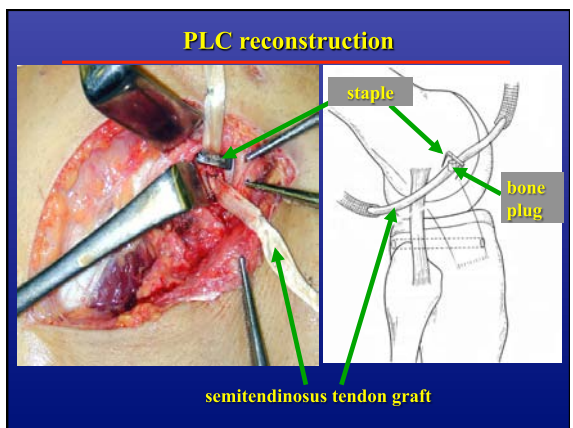
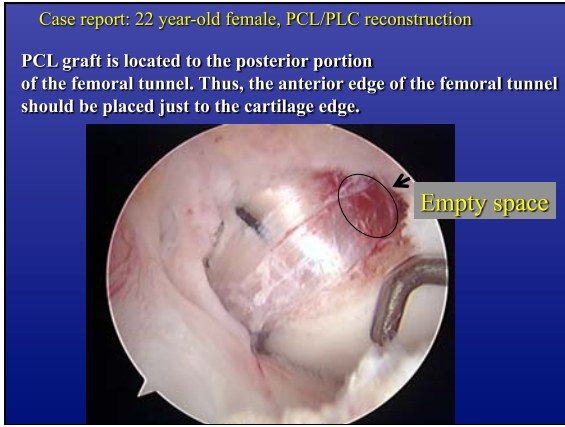
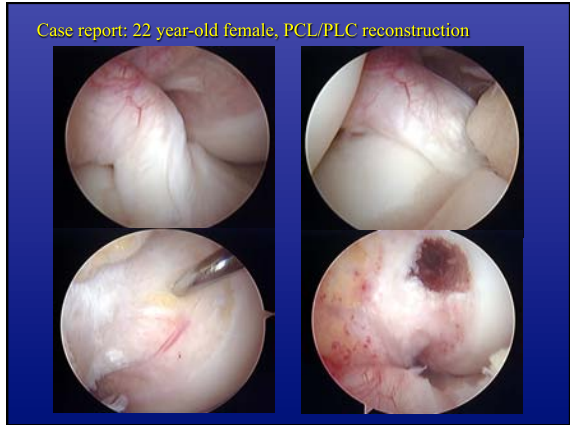
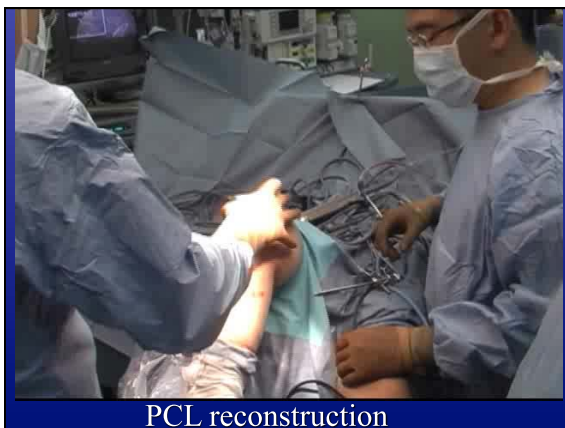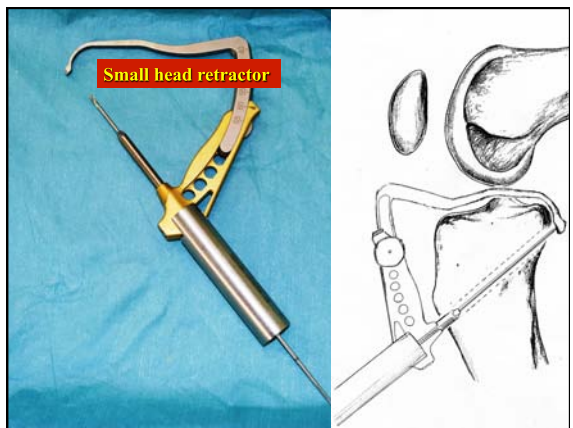
PCL reconstruction

Double vision system and Trans-tibial single bundle augmentation



Ochi, ISAKOS interim workshop in Italy 2002





**7. Structured postoperative rehabilitation**

- 1 wk fixed with knee brace
- 1 wk - apply PCL brace
- 4-6 mos. - PCL brace off
- 9~12mos. - recover for sports




**PCL brace**

**Slow rehabilitation**


Case report: 22 year-old female, PCL/PLC(LCL) reconstruction

**Post-operative X-ray**



Case report: 22 year-old female, PCL/PLC(LCL) reconstruction

**Post-operative stress X-ray**

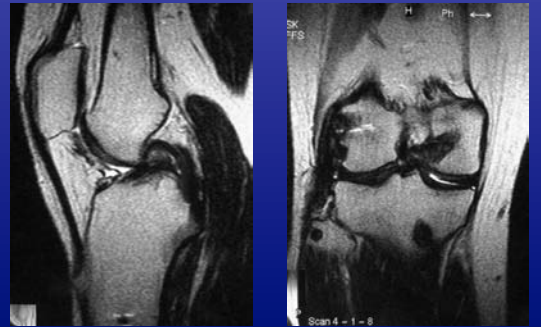


Varus      Posterior      Sagging

Posterior stress: SSD 2mm

Case report: 22 year-old female, PCL/PLC(LCL) reconstruction

**Post-operative MRI**




Case report: 22 year-old female, PCL/PLC(LCL) reconstruction

**P.O. 2y: 2nd look arthroscopy**

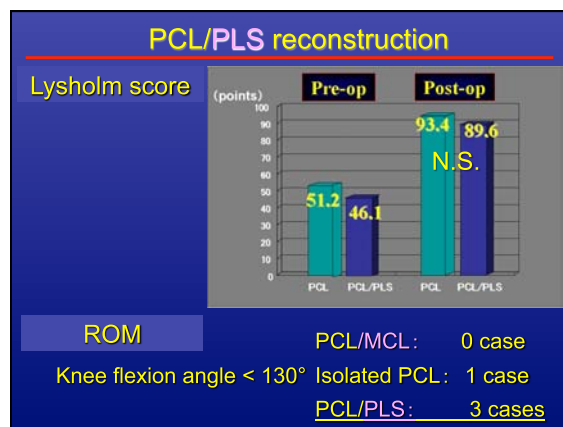



**PCL + PLS reconstruction**

Second look arthroscopy (2 years after primary surgery)



Posterior laxity measured by stress radiography: 3 mm



## Conclusions

---

Our reconstruction procedure of PCL & PLC was introduced.